An interesting cause of hyponatremia

HOSP #		WARD	Red Cross Hospital Oncology ward
CONSULTANT	Dr Amith Ramcharan / Dr Jody Rusch	DOB/AGE	11y Female

Abnormal Result

Persistent hyponatremia

2018 supracellar JPA (Astrocytoma)

Seizures – phenobarb.

Chemo @ 8 y of age.

Vincristin and Carboplatin administration

Craniospinal radiation – leptospinal

Presenting Complaint

Seizures – controlled with Phenobarbital

History

This is an 11 year old patient with a suprasellar JPA (Juvenile Pilocytic Astrocytoma). The tumour was diagnosed at 8y of age, upon which chemotherapy with Vincristine and Carboplatin was initiated. The pituitary was close to the area of radiation therapy as well.

Examination

The patient’s hydration status was normal and there was no cerebral edema.

Laboratory Investigations

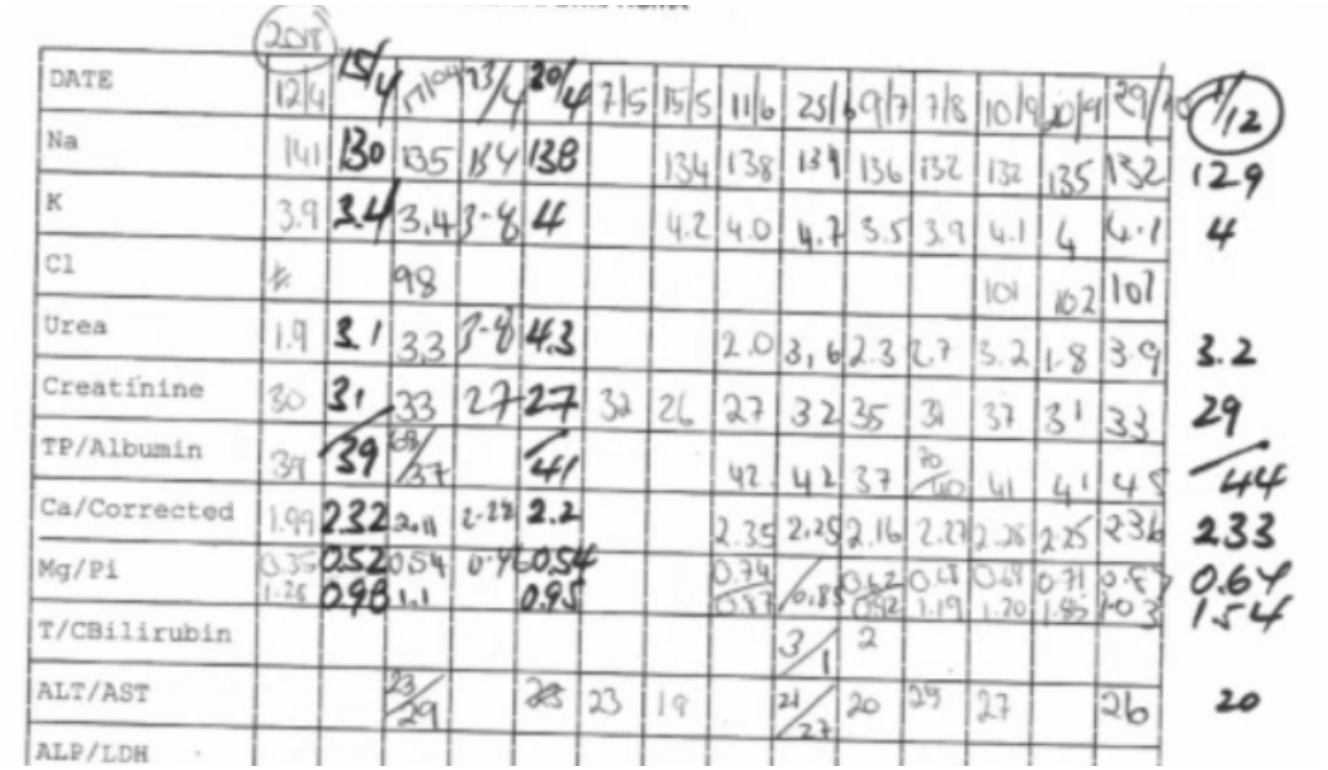

DATE	12/4	15/4	17/04	23/4	20/4	7/5	15/5	11/6	25/6	9/7	7/8	10/9	20/9	29/9	7/12
Na	141	130	135	134	138		134	138	139	136	132	132	135	132	129
K	3.9	3.4	3.4	3-8	4		4.2	4.0	4.7	3.5	3.9	4.1	4	4.1	4
Cl			98									101	102	101	
Urea	1.9	3.1	3.3	3-8	4.3			2.0	3.6	2.3	2.7	3.2	1.8	3.9	3.2
Creatinine	30	31	33	27	27	32	26	27	32	35	31	37	31	33	29
TP/Albumin	39	39	38/37		41			42	42	37	30/40	41	41	45	44
Ca/Corrected	1.99	2.32	2.11	2.22	2.2			2.35	2.25	2.16	2.27	2.26	2.25	2.36	2.33
Mg/Pi	0.35 1.26	0.52 0.98	0.54 1.1	0.76	0.54 0.95			0.74 0.37	0.85	0.62 0.82	0.48 1.19	0.49 1.20	0.71 1.85	0.53 1.03	0.64 1.54
T/CBilirubin									3/1	2					
ALT/AST			23/29		23	23	19		21/27	20	29	27		26	20
ALP/LDH															

2018 – Electrolytes relatively stable

RED CROSS CHILDREN'S HOSPITAL ONCOLOGY SERVICE

METABOLIC MONITORING OF LEUKAEMIA/LYMPHOMA*

	2018						2019					2021		
DATE	27/12	30/12	5/1	8/2	12/3		18/3	29/5	1/10	29/10	22/10	22/2	25/2	
Na	130	128	127	127	130		127	133	136	131		117	128	
K	3.3	3.4	4	4.3	3.7		3.5	3.9	3.5	4.0		4.2	3.7	
Cl		96	95	95	98			102	98	99		82	97	
Urea	3.6	4.1	4.6	2.3	2.2		2.7	1.4	5.2	5.8		3.9	1.6	
Creatinine	27	21	23	22	24		22	32	41	102		34	30	
TP/Albumin	44	42			37		38	39	/ 41			/ 42		
Ca/Corrected	2.35	2.37	2.32		2.28	2.22	2.2	2.57	2.44			2.42		
Mg/Pi	0.65 / 1.17	0.62 / 1.80	0.75 / 1.26		0.68 / 1.32	2.43 / 1.8	0.5 / 1.26	0.76 / 1.46	0.76 / 1.45			0.34 / 1.12		
T/CBilirubin														
ALT/AST												34 / 20		
ALP/LDH												243		
Glucose														
Osmolality													267	

2018-2019 – Hyponatremia and hypomagnesemia developing
The patient was found to have hypothyroidism and started on T4 replacement 50ug mane.

Other Investigations

Urine electrolytes on 23/02/2021:

- Na 54 mM
- K 31.3 mM
- Cl 110 mM
- Osmol 554 mOsmol
- Fractional reabsorption of phosphate: 85%

Final Diagnosis

Unknown – but likely indicates a tubular loss of sodium due to the chemotherapeutic agent(s).

Take Home Message

Chemotherapeutic agents does cause tubulopathy.

TMP/GFR is likely a better indicator of renal phosphate handling than only fractional reabsorption of phosphate. This can be calculated mathematically or read from a nomogram.