

A case of Cryptococcal meningitis with hypomagnesemia

A case of hypomagnesemia and accompanying hypocalcemia with cryptococcal meningitis

Hypocalcemia with Hypomagnesemia

HOSP #		WARD	Internal Medicine ward
CONSULTANT	George vd Watt / Heleen Vreede / David Marais	DOB/AGE	58 y Male

Abnormal Result

Upon signing out blood results:

Calcium = 1.41 mmol/L – Critically low Calcium result

Magnesium = 0.37 mmol/L – Critically low Magnesium

Presenting Complaint

Loss of breath initially accompanied by weight loss.

Upon admission to the ward, patient was slightly delirious, but still able to walk and talk.

History

Patient with metastatic lung cancer and accompanying hypercalcemia, a week prior to the results as at present.

Doctor has given IV Bisphosphonate after the hypercalcemia was noted a week prior (Calcium = 4.23 mmol/L; Alb = 21 g/L; Corrected Ca = 4.61 mmol/L)

Examination

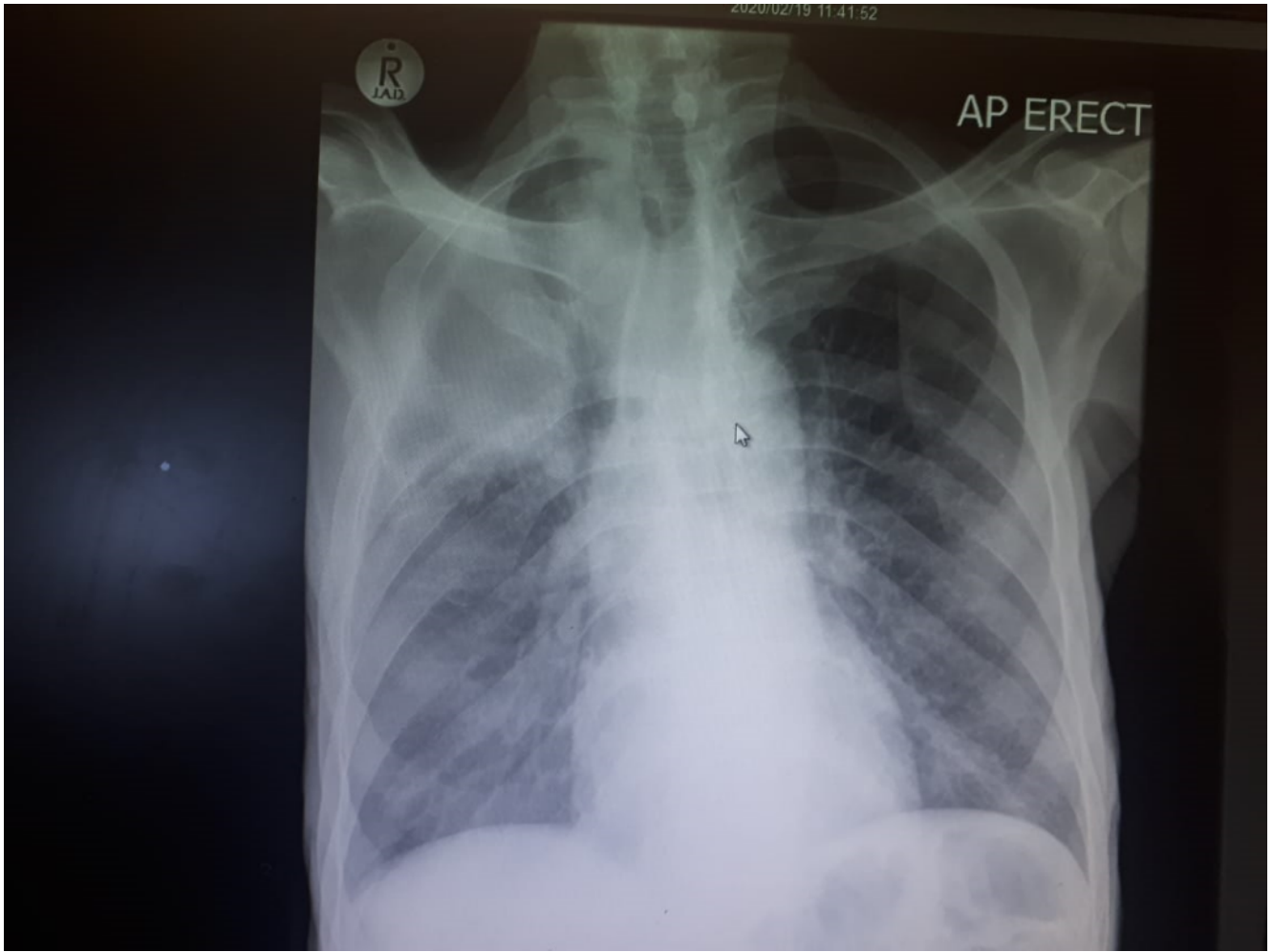
Extensive Crepitations over all the right lung fields.

Laboratory Investigations

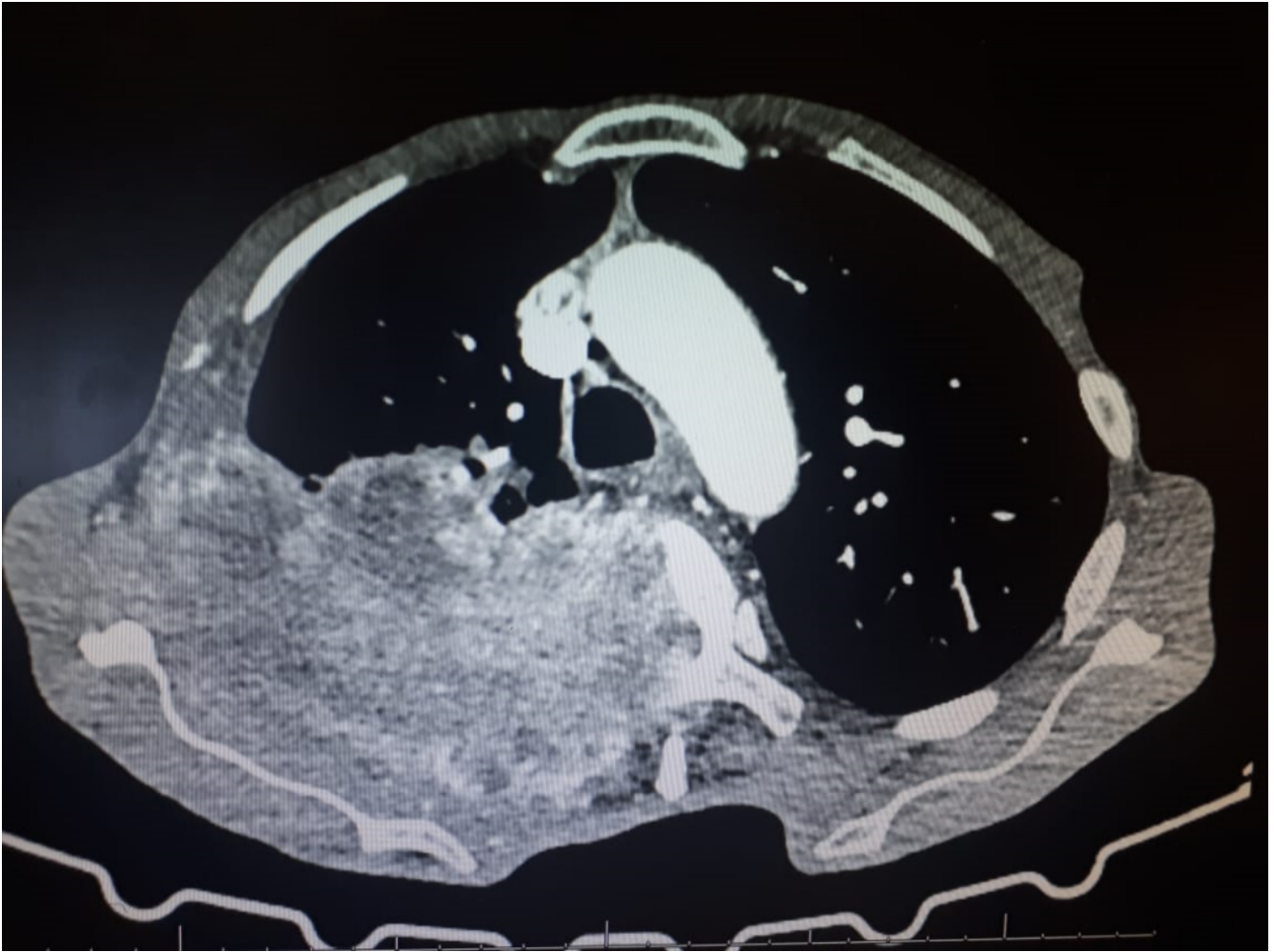
Test Set	Test Item	2020-02-26 11:49	2020-02-25 11:01	2020-02-24 19:20	2020-02-24 11:29	2020-02-23 11:48	2020-02-22 12:28	2020-02-21 16:50	2020-02-20 11:17	2020-02-18 17:07	2020-02-18 14:37	2020-02-17 23:44	2020-02-17 10:42	2020-02-15 3:34	2019-04-23 21:53
Test Set	Test Item														
NA	Na		132 L		133 L	133 L	135 L	138	δ- 139	δ+ 143	δ+ 139		132 L		
K	K		INVH		δ+ 3,4 L	δ- 2,4 L	δ+ 3,0 L	2,4 L	δ+ 2,8 L	δ- 2,1 L	δ- 3,2 L		4		
UREA	Urea		2,6		3,1	5,1	8,4 H	5,8	7,2 H	6,4	9,7 H		10,8 H	12,3 H	
CRT	Creat		44 L		51 L	63 L	82	94	δ+ 109 H	δ- 77	122 H		126 H	143 H	77
CA	Ca	δ- 1,41 L	1,78 L		δ- 1,76 L	δ- 2,02 L			δ+ 3,10 H	δ- 2,32	4,04 H		126 H	143 H	♦ 4,23 H
MG	Mg	0,37 L	δ- 0,38 L		δ+ 0,48 L	δ- 0,29 L							δ- 0,54 L	0,65	
PO4	Phos	δ- 0,51 L	δ+ 2,87 H		0,19 L	δ- 0,16 L							δ- 0,67 L	1,1	
ALB	Alb	25 L						25 L		CEGK	δ+ 28 L		20 L	21 L	
TBIL	tal bili													6	
CBIL	onj bili													2	
ALT	ALT													13	
AST	AST													23	
ALP	ALP													77	
GGT	GGT													29	
LD	LD													138	
PTH	PTH											0,6 L			
HVITDI	al Vit D											17,3			
HVITDI	Comment											VITD2			
HVITDI	HVITDIA											ST2			
HIVVL	VL (raw)													LDL	LDL
FBC	WCC				δ- 6,04									8,58	
FBC	RCC				δ- 2,80 L									3,17 L	
FBC	HB				δ- 7,9 L									9,4 L	
FBC	HCT				0,261 L									0,287 L	
FBC	MCV				93,2									90,4	

[Cumulative results ->Download](#)

Other Investigations



Chest X-Ray AP erect 19/02/2020



CT thorax

Final Diagnosis

Invasive lung CA with “hungry bones” after IV Zoledronic Acid

Vitamin D deficiency, preventing Calcium absorption after the Zoledronic acid started its action of inhibiting bone resorption.

Take Home Messages

CA causes hypercalcemia

Bisphosphonates inhibits bone resorption. Because 99.95% of Ca in the body resides in bone, the effect in serum (the remaining 0.05% of total body Ca) can be significant.

All bisphosphonate drugs share a common phosphorus-carbon-

phosphorus “backbone”:



They differ in the R-groups as above. It binds to calcium hydroxyapatite in bone.

Of the dose infused / absorbed, 50% is excreted unchanged by the kidney, the rest binds to bone tissue, where its elimination half life can apparently be up to 10 years! (UW

Courses

Web

Server-

<https://courses.washington.edu/bonephys/opbis.html>)

Because a bisphosphonate group mimics the structure of pyrophosphate, it can inhibit activation of enzymes that utilize pyrophosphate.



Magnesium follows Calcium levels, but Mg deficiency itself can also cause hypocalcemia.